

# Minimally Invasive Tibial Bone Harvesting Under Intravenous Sedation

Federico Hernández-Alfaro, MD, DDS, PhD, FEBOMS,\* Carlos Martí, MD,†  
María José Biosca, MD, DDS,‡ and Javier Gimeno, MD,§

**Purpose:** Collecting high amounts of autogenous bone often results in considerable donor site morbidity. The hypothesis evaluated with this prospective study is that a modified approach for tibial bone harvesting using a minimally invasive access under local anesthesia plus sedation in an office setting compares favorably in terms of amount of bone harvested, morbidity, and patient satisfaction with more aggressive approaches previously reported.

**Patients and Methods:** Thirty-eight patients (18 women, 10 men) were treated using this method and followed prospectively. A medial approach to the proximal tibia was performed in all cases. A 10 mm incision gives access to an 8 mm manual trephine, which creates a bony window. Cancellous bone is released from the proximal compartment and a bone filter connected to suction allows fast removal of bone particles. Amount of bone harvested (compressed and non-compressed), surgical time, and complications were recorded.

**Results:** Mean surgical time was 14 minutes (range, 9 to 20 minutes). Volume of compressed cancellous bone ranged between 18 and 30 cc (mean, 28 cc).

**Conclusion:** Tibial bone harvesting through a medial minimally invasive approach with a bone filter yields satisfactory results in terms of bone volume, surgical time, and patient satisfaction.

© 2005 American Association of Oral and Maxillofacial Surgeons  
*J Oral Maxillofac Surg* 63:464-470, 2005

The importance of using autogenous bone for reconstruction in the maxillofacial region has already been stressed by different authors.<sup>1-8</sup> Bone harvesting has classically been associated with variable degrees of morbidity. Higher amounts of graft usually correlate with more severe functional and structural compromises at the donor site.<sup>9</sup>

In situations where preprosthetic or reconstructive needs call for bigger grafts, iliac crest has been the site of choice.<sup>10</sup> Morbidity associated with different iliac crest grafting techniques, together with the need in most cases for general anesthesia, has prompted the need to find alternative sites.<sup>11</sup>

Tibial bone harvesting for oral surgical reconstruction has been advocated by several authors.<sup>1-8</sup> Several studies have compared complication rates and amount of bone harvested with this technique with that of iliac crest.<sup>2,3</sup> Conclusions of these studies favor tibial bone harvesting in cases where high amounts of cancellous bone are needed because of the less traumatic approach and low morbidity.<sup>6</sup>

On the anterior surface of the proximal end of the tibia between the condyles, the tibial tuberosity can be palpated as an oval protuberance. Palpation of this tubercle is essential to avoid violation of the articular surface of the tibial plateau and damage to the knee

---

Received from the Universitat Internacional de Catalunya, and the Hospital General de Catalunya and Instituto de Cirugía Maxilofacial, Teknon Medical Center, Barcelona, Spain.

\*Clinical Professor, Oral and Maxillofacial Surgery, Universitat Internacional de Catalunya; and Chief, Department Oral and Maxillofacial Surgery, Hospital General de Catalunya and Instituto de Cirugía Maxilofacial, Teknon Medical Center, Barcelona, Spain.

†Associate Professor, Oral and Maxillofacial Surgery, Universitat Internacional de Catalunya; and Staff, Department of Oral and Maxillofacial Surgery, Hospital General de Catalunya and Teknon Medical Center, Barcelona, Spain.

‡Associate Professor, Oral and Maxillofacial Surgery, Universitat

Internacional de Catalunya; Staff, Department OMFS, Hospital General de Catalunya and Teknon Medical Center, Barcelona, Spain.

§Associate Professor, Oral and Maxillofacial Surgery, Universitat Internacional de Catalunya; Staff, Department OMFS, Hospital General de Catalunya and Teknon Medical Center, Barcelona, Spain.

Address correspondence and reprint requests to Dr Hernández-Alfaro: Instituto de Cirugía Maxilofacial, C/ Vilana, 12. Despacho 185, 08022, Barcelona, Spain; e-mail: director@institutomaxilofacial.com

© 2005 American Association of Oral and Maxillofacial Surgeons

0278-2391/05/6304-0007\$30.00/0

doi:10.1016/j.joms.2004.07.020

joint. We favor medial access to avoid stripping of the tibialis muscle.

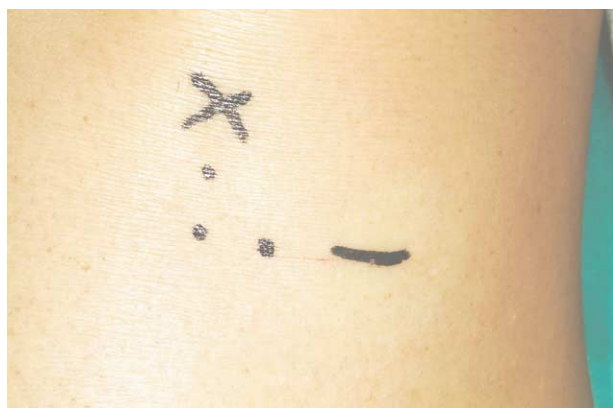Different approaches and methods for recruiting bone from the proximal tibia have been proposed, with variable results regarding amount of bone, and postoperative disturbances.<sup>4,5,8</sup> Most previously reported procedures are either quite traumatic because of the size of the bony window<sup>2</sup> or too slow because of the use of curettes to recover the bone from the cavity.<sup>7</sup> The purpose of this study was to evaluate the amount of collected bone, time consumption, and postoperative recovery of a new minimally invasive tibial bone harvesting technique performed under local anesthesia plus intravenous sedation.

## Patients and Methods

Thirty-eight consecutive patients (18 women, 20 men) were prospectively included in this study. Mean age was 43.6 years (range, 28 to 63 years). All of them underwent unilateral or bilateral sinus grafting with grafts from the proximal tibia under intravenous sedation. Surgery was performed by the same surgeon (F.H.A.) between January 2002 and April 2003, as outpatient procedures at the Departments of Oral & Maxillofacial Surgery from Centro Médico Teknon and Hospital General de Catalunya (Barcelona, Spain).

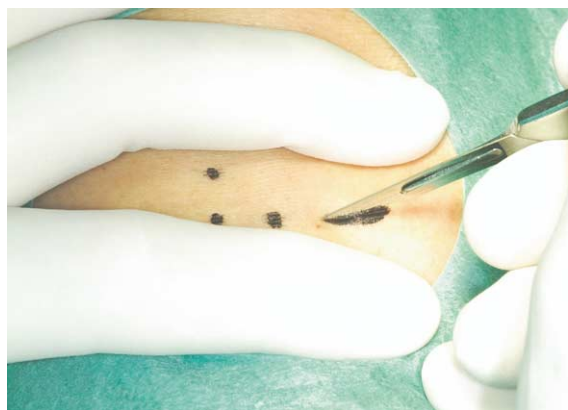Mild intravenous sedation consisting of meperidine and methohexital was administered. Surgical field isolation was achieved through sterile drapes after scrub decontamination with iodine.

A 10 mm horizontal line following skin creases was drawn 2 cm below and 2 cm medially from the anterior tibial tuberosity (Fig 1). One dental carpule of lidocaine (2%) with epinephrine (1:80,000) was infiltrated subcutaneously and at the level of the periosteum.



**FIGURE 1.** References for access to proximal tibia: 2 cm under and 2 cm medial to anterior tibialis tuberosity.

*Hernández-Alfaro et al. Tibial Bone Harvesting Under IV Sedation. J Oral Maxillofac Surg 2005.*



**FIGURE 2.** Through-and-through incision with #10 blade, following a skin crease and going directly to the bone.

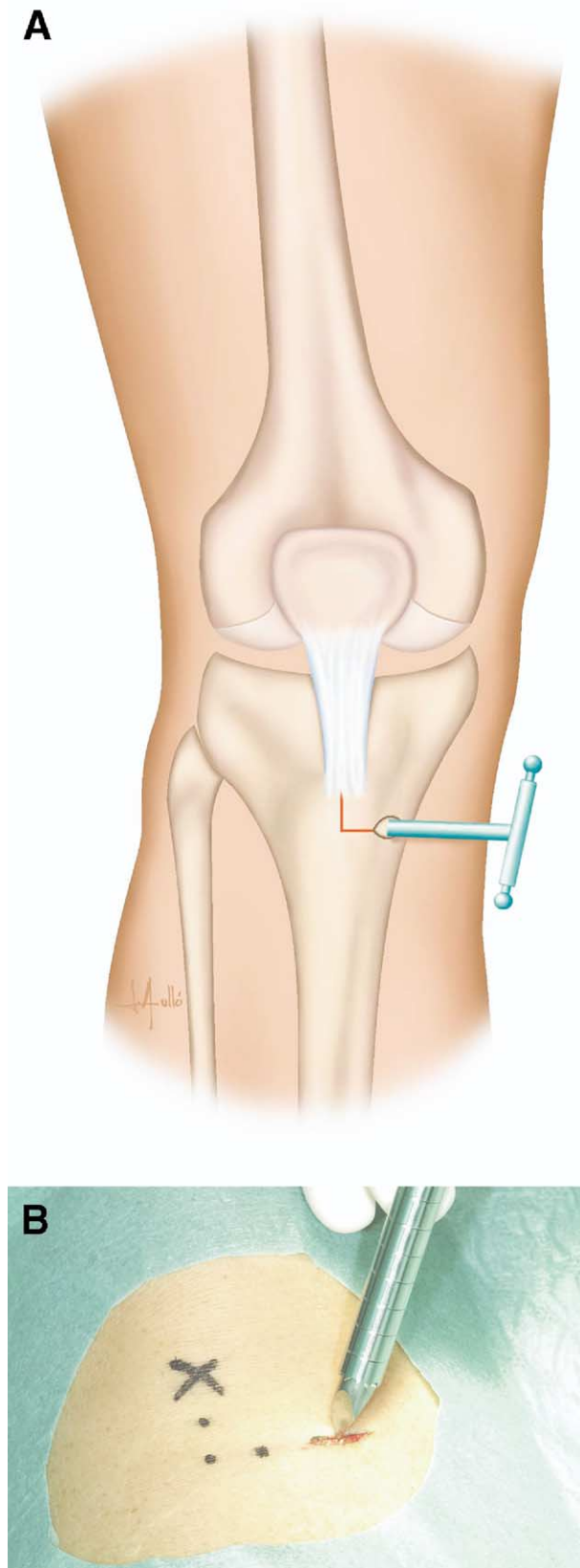
*Hernández-Alfaro et al. Tibial Bone Harvesting Under IV Sedation. J Oral Maxillofac Surg 2005.*

A skin to bone incision was made with a #10 blade (Fig 2). Lateral reflection of the periosteum was made with a sharp periosteal elevator to expose enough bone surface for trephine access.

A manual trephine 8 mm in diameter was used to remove a core of bone of the same size (Fig 3). With the assistance of different sizes of straight and angled bone curettes, cancellous bone was mobilized within the proximal compartment of the tibia (Fig 4). No attempt was made to pull the bone out of the tibia with the curettes because they acted only as scrapers to loosen the cancellous bone from the cortical walls within the compartment. Then a bone filter (Bone-trap; Astra, Malmo, Sweden) connected to suction was used to collect the loose bone (Fig 5). This sequence was made as many times as needed until the cortical walls were clear of cancellous bone. When no further bone was trapped into the bone filter, the compartment was filled up with pressure injected saline. Then, a final filter aspiration of the cavity allowed further recruitment of bone remnants. The bone harvested was already compressed because of the reverse pressure from the suction into the filter (Fig 6).

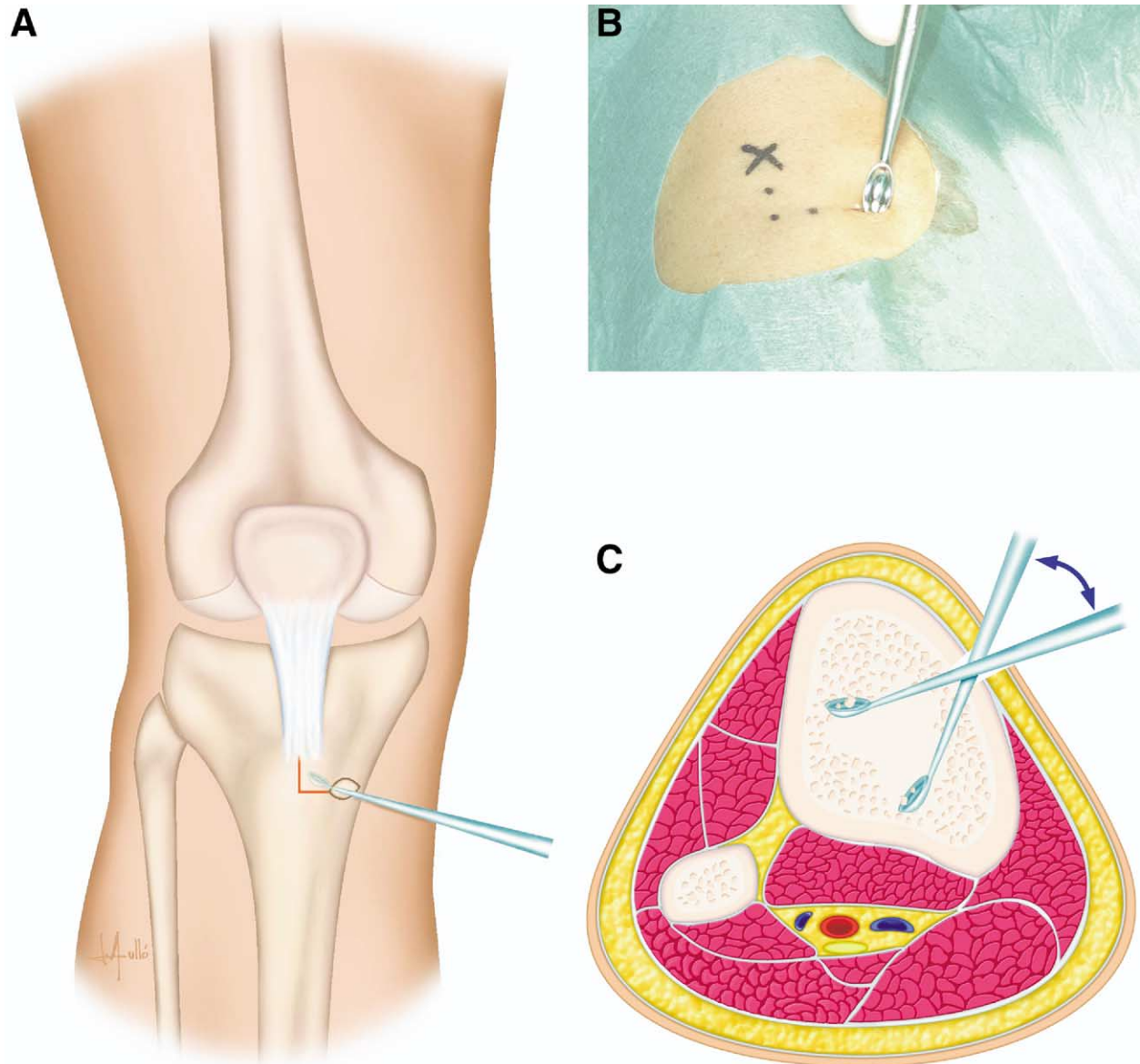
Finally, closing of the wound was made in 3 layers (ie, periosteal, subcutaneous, and subcuticular); the first 2 with interrupted 4.0 poliglactin sutures, the last with running 4.0 nylon (Fig 7). Collected bone was kept in a porcelain dish and then placed into syringes for measurement and distribution into the sinuses (Fig 8).

A light pressure dressing was applied incorporating knee, calf, and ankle. Patients were sent home accompanied right after the procedure. The dressing was removed after the first week together with the subcuticular suture. All patients were placed on antibiotics and nonsteroidal anti-inflammatory drugs for 7 days,



**FIGURE 3.** A, B. Eight mm trephine is manually inserted to open the round bone window.

*Hernández-Alfaro et al. Tibial Bone Harvesting Under IV Sedation. J Oral Maxillofac Surg 2005.*



**FIGURE 4.** A, B, and C. Curette inserted through the window to loosen the cancellous bone.

*Hernández-Alfaro et al. Tibial Bone Harvesting Under IV Sedation. J Oral Maxillofac Surg 2005.*

and instructed to avoid impact loading of the operated leg for the first 2 months.

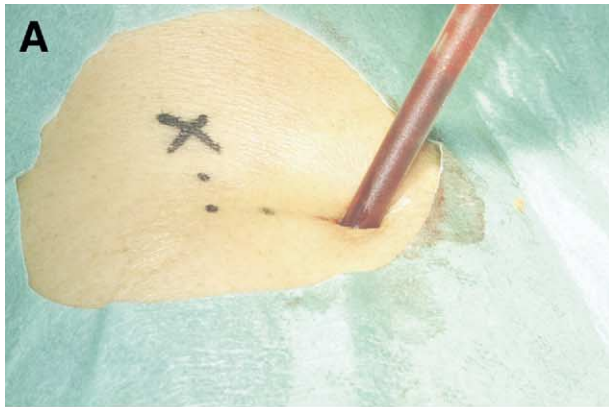Intraoperative information regarding surgical time and amount of collected bone was recorded. Patients were followed weekly postoperatively and examined for gait disturbances and wound complications.

## Results

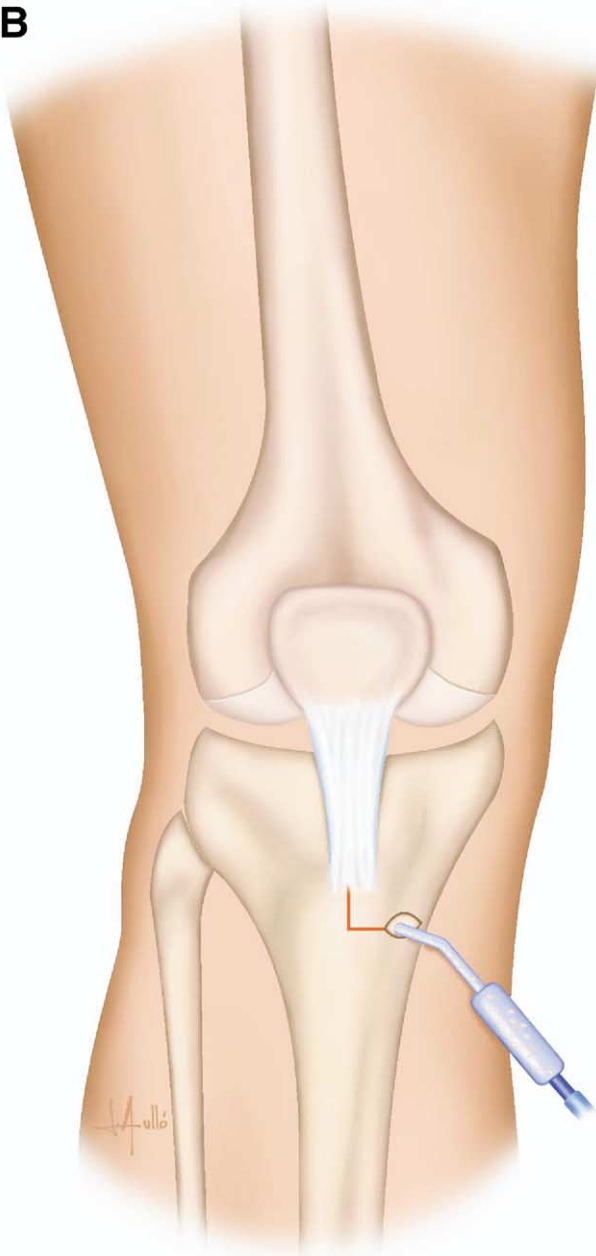
A total of 38 procedures were performed over a period of 15 months, using this minimally invasive medial approach to the proximal tibia. All the procedures were made together with unilateral or bilateral sinus lifts. Patients included 18 women and 20 men.

Mean age of patients was 43.6 years (range, 28 to 63 years). The mean surgical time from >incision to last suture was 14 minutes (range 9 to 20). The mean volume of compressed cancellous bone obtained per site was 28 cc (range, 18 to 30 cc).

Seven patients described unpleasant scraping sensations during the procedure, but none of them complained of pain. Two patients (women) experienced moderate edema lasting 2 weeks. Three patients complained of gait disturbances for 3 and 4 weeks, respectively. Two patients suffered suture dehiscence which secondarily healed uneventfully. All of the patients (100%) stated that they would undergo the same procedure again if necessary.

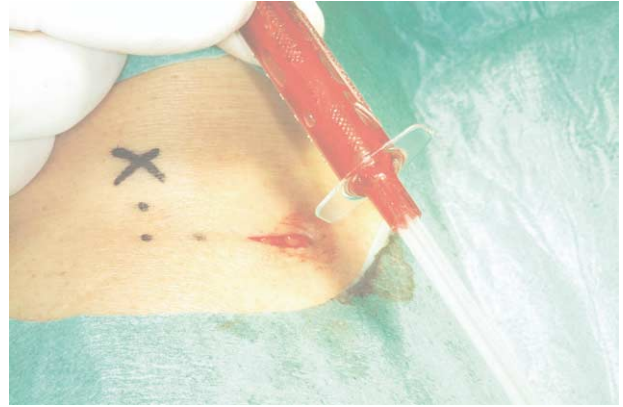

B



**FIGURE 5.** A bone filter connected to suction is inserted through the hole to capture and remove the bone.

*Hernández-Alfaro et al. Tibial Bone Harvesting Under IV Sedation. J Oral Maxillofac Surg 2005.*

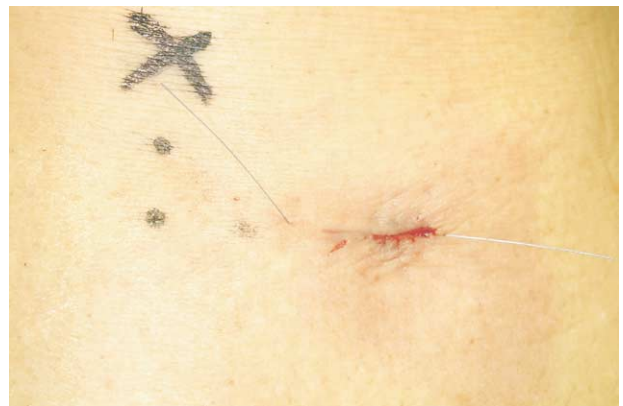

**FIGURE 6.** Full filter ready to be emptied into the porcelain dish.

*Hernández-Alfaro et al. Tibial Bone Harvesting Under IV Sedation. J Oral Maxillofac Surg 2005.*

## Discussion

Previous studies have pointed out the advantages of using the proximal tibia as a donor site when high amounts of cancellous bone are needed.<sup>2</sup> Tibial bone harvesting has less morbidity than iliac crest harvesting.<sup>3</sup> The latter requires general anesthesia in most instances, and pain control constitutes a critical issue.<sup>10</sup> Equal amounts of bone graft material are available for harvest from the medial and lateral aspects of the proximal tibia.<sup>8</sup> Incision size relates to the size of the bone window (Fig 9). It varies between different series between 1 and 3 cm.<sup>2,4</sup> With our proposed approach, a 1 cm incision suffices to place the 8 mm trephine. This reduced approach is important to avoid visible scars and reduce postoperative discomfort. The same principle applies when deciding the direction of the incision. Some authors have proposed oblique incisions.<sup>2,8</sup> We try to place them parallel to skin tension creases to minimize unaesthetic scars, espe-



**FIGURE 7.** Subcuticular 4.0 suture.

*Hernández-Alfaro et al. Tibial Bone Harvesting Under IV Sedation. J Oral Maxillofac Surg 2005.*

cially in women. The incision with our technique is placed 2 cm under and 2 cm medial to the anterior tuberosity. At this point, thickness of subcutaneous tissues is minimal. This allows us to make a through-and-through incision with minimal trauma and bleeding.

The minimally invasive medial approach used with this group of patients has proven to be very efficient in terms of time consumption (mean, 14 minutes), and amount of bone harvested (mean, 28 cc). This compares favorably with other series. Marchena et al<sup>7</sup> report a mean time for harvesting of 58 minutes, with 11.3 cc of mean harvested bone. They describe collection of the bone by curettes.<sup>7</sup> This method requires a bigger skin incision and bone access and can be extremely time consuming. Using bone filters for the actual collection of bone after loosening it with curettes significantly reduces operating time. Time reduction also favorably influences the amount of sedative drugs needed, blood loss, and postoperative recovery. Thus, patients can be discharged from the office soon after the procedure.

Medial approach to the proximal tibia has proven as effective as the lateral one in terms of amount of collected bone.<sup>8</sup> This approach compared with the lateral one is safer and avoids potential injury to important structures (ie, tibialis muscle, anterior tibial recurrent artery). Only insertions of the semi-membranous muscle are to be avoided.

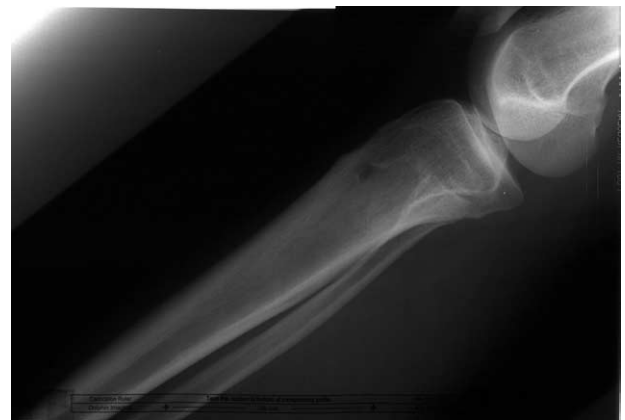A recent experimental study suggests that the risk of postoperative fracture is not increased with tibial bone harvesting.<sup>12</sup> However, care should be taken when displacing the curette under the tibial plateau to avoid fractures.

The harvested bone is already recovered in a compressed fashion. The bone filter eliminates the liquids and compresses the bone through the suction's re-



**FIGURE 8.** Collected bone.

*Hernández-Alfaro et al. Tibial Bone Harvesting Under IV Sedation. J Oral Maxillofac Surg 2005.*



**FIGURE 9.** X-ray illustrating the reduced access required to empty the proximal third of the tibia.

*Hernández-Alfaro et al. Tibial Bone Harvesting Under IV Sedation. J Oral Maxillofac Surg 2005.*

verse pressure. Thus, no further compression of the material is required.

Patient satisfaction encourages the use of this method for tibial bone harvesting in cases where blocks of bone are not needed. The ease and predictability of the technique allows in-office procedures.

We conclude that tibial bone harvesting can be safely performed through a limited medial approach with bone filter under local anesthesia plus sedation. This technique compares favorably with previous approaches in terms of amount of bone harvested, morbidity, and patient satisfaction. Iliac bone grafting should be reserved for situations where blocks of autogenous bone are needed.

#### Acknowledgment

The authors thank Dr Marta Cirach, DDS for her assistance in preparing the manuscript.

#### References

1. O'Keefe RM, Reimer BL, Butterfield SL: Harvesting of autogenous cancellous bone graft from the proximal tibia metaphysis: A review of 230 cases. *J Orthop Trauma* 5:469, 1991
2. Catone GA, Reimer BL, McNeir D, et al: Tibial autogenous cancellous bone as an alternative donor site in maxillofacial surgery: A preliminary report. *J Oral Maxillofac Surg* 50:1258, 1992
3. Ilankovan V, Stronczek M, Telfer M, et al: A prospective study of trephined bone grafts of the tibial shaft and iliac crest. *Br J Oral Maxillofac Surg* 36:434, 1998
4. Van Damme PA, Merkx MAV: A modification of the tibial bone graft harvesting technique. *Int J Oral Maxillofac Surg* 25:246, 1996
5. Besly W, Ward-Booth P: Technique for harvesting tibial cancellous bone modified for use in children. *Br J Oral Maxillofac Surg* 37:129, 1999
6. Silva RG: Donor site morbidity and patient satisfaction after harvesting iliac and tibial bone. *J Oral Maxillofac Surg* 54:28, 1996

7. Marchena JM, Block MS, Stover JD: Tibial bone harvesting under intravenous sedation: Morbidity and patient experiences. *J Oral Maxillofac Surg* 60:1151, 2002
8. Herford AS, Brett JK, Audia F, et al: Medial approach for tibial bone graft: Anatomic study and clinical technique. *J Oral Maxillofac Surg* 60:358, 2003
9. Ahlmann E, Patzakis M, Roidis N, et al: Comparison of anterior and posterior iliac crest bone grafts in terms of harvest-site, morbidity and functional outcomes. *J Bone Joint Surg Am* 84A:716, 2002
10. Bloomquist DS, Feldman GR: The posterior ilium as a donor site for maxillo-facial bone grafting. *J Maxillofacial Surg* 8:60, 1980
11. Mazock JB, Sterling RS, Triplett G: Posterior iliac crest bone harvest: Review of technique, complications, and use of an epidural catheter for postoperative pain control. *J Oral Maxillofac Surg* 61:1497, 2003
12. Alt V, Meeder PJ, Seligson D, et al: The proximal tibia metaphysis: A reliable donor site for bone grafting? *Clin Orthop* 4:315, 2003