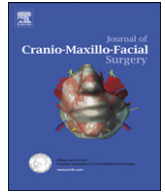



Contents lists available at ScienceDirect

## Journal of Cranio-Maxillo-Facial Surgery

journal homepage: www.jcmfs.com



## 3D planning in orthognathic surgery: CAD/CAM surgical splints and prediction of the soft and hard tissues results – Our experience in 16 cases

Samir Aboul-Hosn Centenero\*, Federico Hernández-Alfaro

*"Instituto de Cirugía Maxilofacial e Implantología" (Head of the Institution: Dr Federico Hernández-Alfaro), Clínica Teknon, C/Vilana, 12, Office 185, 08022 Barcelona, Spain*

### ARTICLE INFO

#### Article history:

Paper received 26 August 2009

Accepted 1 March 2011

#### Keywords:

Orthognathic planning

CAD/CAM technology

Surgical splint

Postoperation prediction result

### ABSTRACT

The aim of this article is to determine the advantages of 3D planning in predicting postoperative results and manufacturing surgical splints using CAD/CAM (Computer Aided Design/Computer Aided Manufacturing) technology in orthognathic surgery when the software program Simplant OMS 10.1 (Materialise®, Leuven, Belgium) was used for the purpose of this study which was carried out on 16 patients. A conventional preoperative treatment plan was devised for each patient following our Centre's standard protocol, and surgical splints were manufactured. These splints were used as study controls. The preoperative treatment plans devised were then transferred to a 3D-virtual environment on a personal computer (PC). Surgery was simulated, the prediction of results on soft and hard tissue produced, and surgical splints manufactured using CAD/CAM technology. In the operating room, both types of surgical splints were compared and the degree of similitude in results obtained in three planes was calculated. The maxillary osteotomy line was taken as the point of reference. The level of concordance was used to compare the surgical splints. Three months after surgery a second set of 3D images were obtained and used to obtain linear and angular measurements on screen. Using the Intraclass Correlation Coefficient these postoperative measurements were compared with the measurements obtained when predicting postoperative results. Results showed that a high degree of correlation in 15 of the 16 cases. A high coefficient of correlation was obtained in the majority of predictions of results in hard tissue, although less precise results were obtained in measurements in soft tissue in the labial area. The study shows that the software program used in the study is reliable for 3D planning and for the manufacture of surgical splints using CAD/CAM technology. Nevertheless, further progress in the development of technologies for the acquisition of 3D images, new versions of software programs, and further studies of objective data are necessary to increase precision in computerised 3D planning.

© 2011 European Association for Cranio-Maxillo-Facial Surgery.

### 1. Introduction

Over a period of four years several articles highlighted the importance of three-dimensional (3D) planning in orthognathic surgery (Juergens et al., 2006; Marchetti et al., 2006; Swennen et al., 2008; Olszewski et al., 2010). In this paper we present our experience with numerical results in terms of prediction results and accuracy of the surgical splints using 3D planning. Accurate treatment planning is an important element of orthognathic surgery if optimum aesthetic and occlusal results are to be obtained (Eckhardt and Cunningham, 2004).

Preoperative planning requires the collection of data in order to make a precise diagnosis of the dento-skeletal deformity and devise a treatment plan which is then reproducible in the operating

room (Ellis, 1999). Traditionally this preoperative data has been obtained from different sources: physical examination, lateral telerradiography, dental casts, face bow, articulators and photographs.

Advances in 3D imaging technology have resulted in a series of projects designed to provide new computerised tools for use in preoperative planning and the manufacture of surgical splints (Xia et al., 2000; Gateno et al., 2007; Swennen et al., 2009a,b,c; Schendel and Jacobson, 2009).

Computed tomography (CT) and, more recently, cone-beam computed tomography (CBCT) provide volumetric images of the anatomic structure of a patient's face. Using a sequence of computerised mathematical algorithms, these data can be converted into 3D images of a patient's craniofacial skeleton and the soft tissue covering it (Marchetti et al., 2006, 2007). It is also possible to interact with these 3D images simulating the surgery that will take place and producing predictions as to the postoperative outcome in soft and hard tissues.

\* Corresponding author. Chief of the Maxillofacial Unit, Hospital Plató, C/ Plató, 21, Office #4, 08006 Barcelona, Spain. Tel.: +34 609518571.

E-mail address: samiraboul@hotmail.com (S. Aboul-Hosn Centenero).

Different software programs are available for 3D planning and the manufacture of surgical splints using CAD/CAM (Computer Aided Design/Computer Aided Manufacturing) technology (Xia et al., 2007; Metzger et al., 2008; Swennen et al., 2009a,b,c). The manufacture of CAD/CAM surgical splints has introduced a working methodology which is different from conventional clinical practice. The ability to work in a computerised 3D environment has led to what is now known as 3D planning – the subject of this article.

The move from 2D to 3D imaging provides surgeons and patients with extra information that cannot be obtained from lateral tele-radiography alone. The software program enables the surgeon to interact with the 3D images and all data can be stored on computer files, which facilitates data management. All preoperative information can be shared with colleagues, in any part of the world, quickly and easily using the Internet. Although studies have been carried out on a number of the software programs, not all of these can store preoperative data in one place and provide access to images which serve to simulate surgery, draw osteotomy lines, plan 3D treatment with the prediction of postoperative outcomes and construct surgical splints using CAD/CAM technology.

The aim of this article is to evaluate the precision of 3D planning in patients with dento-skeletal malformations using the software program SimPlant® Pro OMS 10.1 (Materialise®, Leuven, Belgium) to:

- produce surgical splints using CAD/CAM technology
- predict postoperative outcomes in soft and hard tissue.

## 2. Material and methods

A prospective study was carried out in a group of 16 consecutive patients who volunteered to take part in the study. All the patients had a dento-skeletal deformity which required surgical and orthodontic treatment. Informed consent, confirmed by the signing of a form, was obtained from all the patients. The same surgeon operated on all the patients.

After evaluation by the Ethics Committee of the Universitat Internacional de Catalunya (UIC) Barcelona, Spain, the study was carried out. In fifteen cases bimaxillary surgery was performed and in one case single jaw surgery was performed (Table 1).

In all cases treatment was planned following the standard protocol used at the Institute for Maxillofacial Surgery and Implantology of the Centro Médico Teknon (Barcelona, Spain). This involved:

- Clinical examination
- Photographs: pictures of the dental occlusion and oblique, frontal, and lateral views of the face

**Table 1**

Patients operated in the study with their dentofacial deformity and the treatment done.

Patients (n)	Dentofacial deformity	Surgical treatment
1	Occlusion class III. Long face, upper jaw hypoplasia	Bimaxillary surgery with upper jaw segmentation
2	Occlusion class III. Upper jaw hypoplasia	Bimaxillary surgery
3	Occlusion class III. Upper jaw hypoplasia. Mandibular asymmetry	Bimaxillary surgery with upper jaw segmentation
4	Occlusion class II. Mandibular hypoplasia	Bimaxillary surgery
5	Occlusion class II. Upper jaw and mandibular hypoplasia	Bimaxillary surgery
6	Occlusion class II. Mandibular hypoplasia	Mandibular sagittal split and mentoplasty
7	Occlusion class III. Upper jaw hypoplasia	Bimaxillary surgery
8	Occlusion class III. Hypoplasia maxilar anteroposterior, laterodesviación mandibular	Bimaxillary surgery
9	Occlusion class II. Long face. Upper jaw hypoplasia, mandibular hypoplasia	Bimaxillary surgery with upper jaw segmentation
10	Occlusion class II. Long face. Upper jaw vertical hyperplasia, Mandibular hypoplasia	Bimaxillary surgery with mentoplasty
11	Occlusal class III. Upper jaw hypoplasia with asymmetric mandibular hyperplasia	Bimaxillary surgery with upper jaw segmentation
12	Occlusal class II. Vertical upper jaw hyperplasia and mandibular hypoplasia	Bimaxillary surgery with upper jaw segmentation
13	Occlusion class II with long face	Bimaxillary surgery with mentoplasty
14	Occlusion class III. Upper jaw hypoplasia with mandibular asymmetry	Bimaxillary surgery
15	Occlusion class II. Vertical upper jaw hypoplasia. Mandibular asymmetry	Bimaxillary surgery
16	Occlusion class II. Vertical upper jaw hyperplasia and mandibular hypoplasia	Bimaxillary surgery

- A radiographic study: orthopantomogram; craniofacial tele-radiography frontal and profile; and computed tomography (CT: General Electric HiSpeed CTE single slice) or cone-beam computed tomography (CBCT: IS I-CAT 17-23), using a wax bite wafer to keep patients in centric relation during the study. Pre- and postoperative images were obtained for the first ten patients using CT and the images for the remaining six patients were obtained using CBCT in which the field of vision (FOV) had been increased to a height of 17 cm and a diameter of 23 cm. This allowed all the anatomical structures necessary for our 3D planning to be visualised. CBCT was used in the last six patients because the Institute acquired the CBCT after our study had already begun. Because of the advantages of CBCT with regard to patients' comfort during the study and the smaller doses of radiation, the decision was made to modify the study protocol
- Simulation of the facial arch and plaster dental models in a semi-adjustable SAM-2 articulator (Great Lakes Orthodontic Products, Ltd. Tonawanda, NY)
- Production of conventional acrylic surgical splints. These surgical splints were used as controls to compare with splints made using CAD/CAM technology.

Once planning had been carried out using the Institute's standard protocol, the process of obtaining 3D images began with which to create a 3D treatment plan and manufacture the surgical splints using CAD/CAM.

The following is a step-by-step description of the process followed:

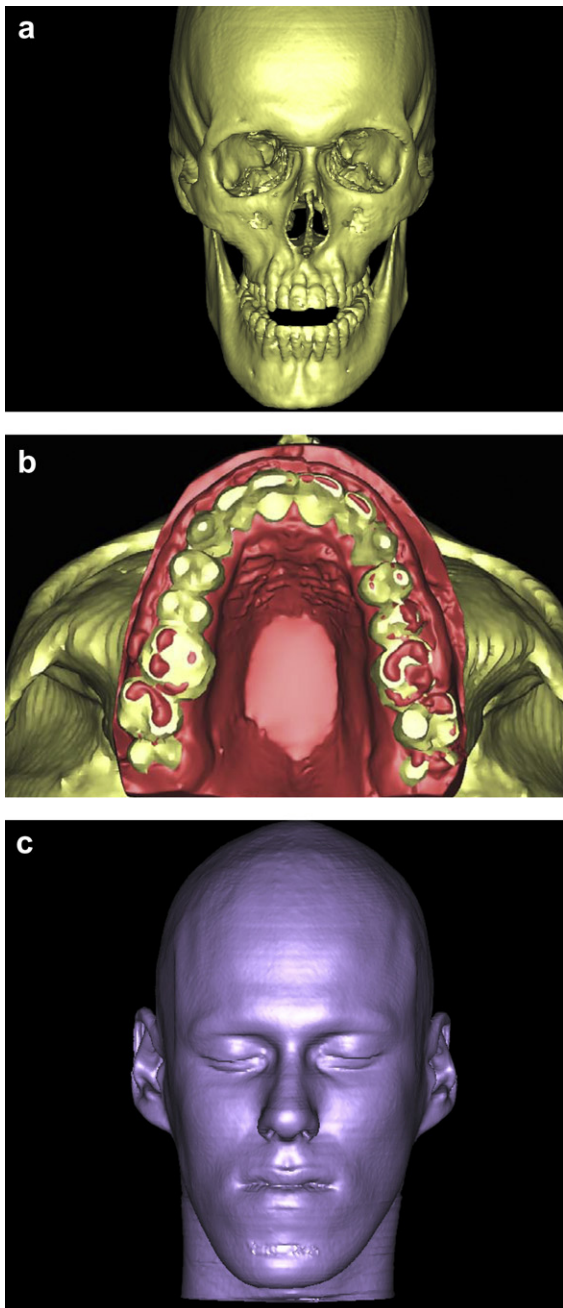
### 1. Three-dimensional image acquisition

When the images were obtained using CT, with the patient in a supine position, the Frankfurt Plane was perpendicular to the horizontal (the floor). When the images were obtained using CBCT, the Frankfurt Plane was parallel to the horizontal plane. In both cases the patient's head was placed in the natural head position by trained auxiliary personnel. All the images obtained were stored in Digital Imaging Communication in Medicine (DICOM) format and sent to a CAD/CAM Centre (Materialise®, Leuven, Belgium) by Internet using an FTP file. The patients' dental casts were also sent to the Centre by courier service.

Neither CT or CBCT provided accurate enough images of the patient's dental structure, so the dental casts were scanned using an optical 3D laser with a resolution of 20 µ, to visualise the 3D models via surface rendering. This gave precise details of the shape and size of the patient's teeth.

At the same time, segmentation of the CT- or CBCT-images sent to the Centre was carried out. Using mathematical algorithms the DICOM images were converted into 3D images. As a result, 3D images were obtained of each patient's craniofacial skeleton, surrounding soft tissue, and teeth. Once the images had been processed they were uploaded onto a PC (Sony Vaio VGN-FE21M).

The registration between the patient scan and the scan of the plaster dental casts was carried out using a semi-automatic procedure, starting from a surface registration in selected zones where accurate tooth information was available in the CT-images. The result was further fine-tuned if necessary by manually moving and rotating the cast while inspecting the contours of the plaster models in the CT-images. As a final quality check the contours were inspected in all slices and in all three dimensions (axial, coronal and sagittal).



**Fig. 1.** (a) 3D images of craniofacial skeleton. (b) 3D images of the patient with superimposed 3D images of dental models. (c) 3D images of soft tissue.

The CAD/CAM Centre sent back to the Institute, via the Internet, 3D images of the patient's craniofacial skeleton together with images of their dental casts superimposed on their dental arches and images of facial soft tissue surrounding these structures. Three-dimensional images were now available of hard tissue, teeth and soft tissue (Fig. 1a–c).

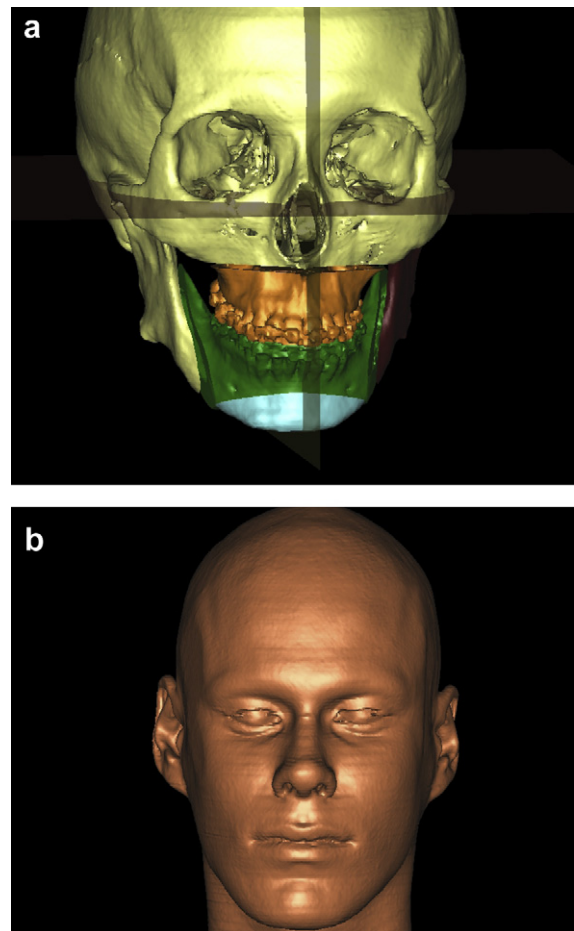
## 2. 3D planning

Using these 3D images it was possible to perform osteotomies, reposition of osteotomized bony structures, control intercuspation, control interferences between osteotomized bony structures and regions at the base of the skull, and simulate the postoperative results on hard and soft tissue in 3D on our computer screen (Fig. 2a and b).

## 3. CAD/CAM surgical splints

Our 3D treatment plan was sent to the CAD/CAM Centre so that they could manufacture stereolithographic surgical splints which were returned to us by conventional mail within 5 days (Fig. 3a and b).

No independent 3D planning was carried out although the results of the conventional treatment plan were transferred to our computer screen. The same movement of the dental arches which had been carried out in the articulator during model surgery was simulated in 3D. The software under study includes algorithms for finding the



**Fig. 2.** (a) 3D surgical simulation showing osteotomy lines and mobilisation of the osteotomised bones. (b) Three-dimensional simulation of the predicted results on facial soft tissues after repositioning the mobilised bone structures.

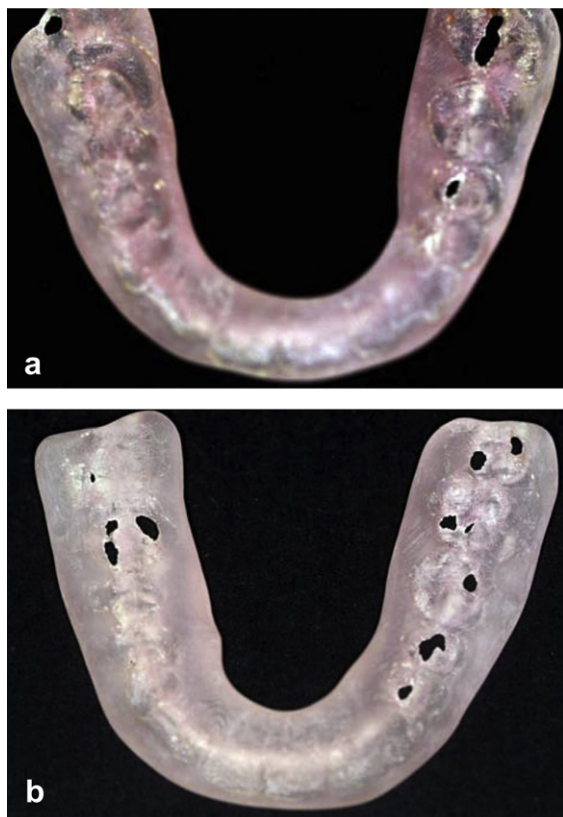


Fig. 3. (a) Final CAD/CAM surgical splint. (b) Intermediate CAD/CAM surgical splint.

correct occlusion. This was particularly useful when evaluating the points of contact to obtain the best possible occlusion. Once surgery had been simulated, different linear and angular measurements from the preoperative 3D images were used to determine the precision of the prediction of results. These measurements (Table 2) were taken between points at the base of the skull – which did not change their position after surgery, and points that would change their position after surgery, e.g. the Menton (Me).

Three months after surgery, patients were subjected to the same study as in the preoperative planning stage and a second set of images was obtained in DICOM format using CT or CBCT. These images were sent to the CAD/CAM Centre where, after a process of segmentation, 3D images were obtained that enabled the post-operative measurements to be contrasted with the predicted results obtained from the preoperative data.

## 2.1. Statistical analysis

### 2.1.1. Comparison of surgical splints

A descriptive analysis of the Level of Concordance was used to compare the similarity between CAD/CAM and conventional surgical splints. To do this, measurements were taken at the level of the osteotomized maxillary bone during surgery. Taking as a reference the immobile segment (the bone above the osteotomized segment) of the maxilla, the space between this segment and the osteotomized segment was measured in the anteroposterior and transversal planes for both types of splints. The position of the upper maxilla in the vertical plane was defined in our treatment plan taking intraoral points (such as the lateral incisor crown), the infraorbital foramen and soft tissue (internal palpebral rim) as references. Three levels of concordance were defined for the intermediate surgical splints that enabled a descriptive analysis of the results obtained:

**Table 2**  
Display of the Intraclass Correlation Coefficient (ICC) and its level of significance of each of the measurements studied in the 16 cases that form the study.

	ICC	Confidence interval at 95%		Significance
		Inferior limit	Superior limit	
AF	0.880	0.687	0.958	<0.001
AnF	0.910	0.758	0.969	<0.001
ANL	0.954	0.870	0.984	<0.001
pL_Fr_Md	0.608	0.162	0.849	0.007
pL_Fr_Oc	0.375	-0.178	0.739	0.085
pL_Oc_Md	0.350	-0.204	0.726	0.101
Ns_Bs_A	0.814	0.542	0.933	<0.001
Ns'_Bs_A'	0.975	0.927	0.992	<0.001
Ns_Bs_Me	0.875	0.667	0.957	<0.001
Bs_Me	0.964	0.899	0.988	<0.001
Ns'_Bs_Me'	0.917	0.770	0.971	<0.001
Bs_Me'	0.947	0.847	0.982	<0.001
Rac-Tn-Lac	0.624	0.186	0.855	0.002
DistInteralar	0.561	0.094	0.827	0.005
Li_Plest	0.943	0.839	0.980	<0.001
Stomio_PIOc	0.053	-0.416	0.524	0.418
Upper lip height	0.540	0.090	0.814	0.012

Facial Height (AF): distance between Ns (point of union between the frontal bone and the bones of the nose) and Me (lower and medial point at mandibular symphysis region).

Facial Angle (AnF): angle between the Frankfurt Plane (formed by the two Orbital points: Or, located in the lower orbital inferior rim region and the point located between the two Porions or Po: upper external auditory meatus) and a vertical plane that goes through Ns and two points at the Pogonion level (Pg: located in the most convex point of the chin).

Nasolabial Angle (ANL): formed by the Ls (highest superior point and medial point of the upper vermillion), Sn (subnasal point or union point between the nasal columella and the filtrum labiale point) and the nasal tip.

(pL\_Fr\_Md): angle formed between the Frankfurt Plane and the Mandibular Plane (formed by two points located in the mandibular angles and the Me).

(pL\_Fr\_Oc): angle formed between the Frankfurt Plane and the Occlusal Plane (formed by the maxima intercuspation points of the first molars and by a medial point in the incisal occlusal region).

(pL\_Oc\_Md): angle formed between the Occlusal Plane and the Mandibular Plane.

Angle Ns\_Bs\_A. (Bs: most anterior point of the foramen magnum. A: most concave point and medial point at the maxilla bone level).

Angle Ns'\_Bs\_A'. (Ns': projection of Ns on soft tissue. A': projection of A on soft tissue).

Angle Ns\_Bs\_Me.

Angle Ns'\_Bs\_Me'. (Me': projection of Me on soft tissue).

Distance Bs\_Me.

Distance Bs\_Me'.

Rac-Tn-Lac: angle between right alar cartilage-tip of the nose-left alar cartilage.

Interalar Nasal Distance (Distinteralar): between the two most convex points of both nasal wings.

Li\_Plest: distance between Labral inferius and Aesthetic plane (E-line extending from the soft-tissue tip of the nose to the soft-tissue chin point).

Distance between Stomio and Occlusal plane (Stomio\_PIOc).

Upper lip height (AltIabsup) (distance between medial point of the upper vermillion and Sn point).

- High level of concordance: when the difference between both types of surgical splints was <1 mm in the three planes.
- Moderate level of concordance: when the difference between both types of surgical splints was <1 mm in two planes.
- Low level of concordance: when the difference between both surgical splints was <1 mm in one or none of the planes.

We believe it to be very important that surgical splints should be compared in the operating room since it is an 'authentic' scenario in which our preoperative planning is transferred to the patient and where we can evaluate in practice whether both types of surgical splints provide the same results for the same treatment planning. Final surgical splints were not compared since a correct type I occlusion was achieved with both the conventional and CAD/CAM splints. In the case of the patient with the single jaw osteotomy the surgical splint used was considered intermediate.

### 2.1.2. Analysis of the prediction of the results

The Intraclass Correlation Coefficient (ICC) was used for the statistical analysis of the degree of precision in the prediction of results. The erroneous use of the correlation coefficient was thus avoided since a high level of correlation ('r') could have been obtained with a low level of concordance in studies in which two quantitative variables are analysed. Linear and angular measurements of the hard and soft tissues were made (Table 2). These measurements were made at the preoperative stage in our 3D simulation, and at the postoperative stage three months after surgery using 3D images obtained when patients were subjected to the same study as was carried out at the preoperative stage. The intraclass correlation coefficient ranged between 0 (no correlation) and 1 (total correlation) to consider statistically significant values with  $p < 0.05$ . To a certain extent the interpretation of these data is arbitrary although consensus exists with regard to the results as shown in this article (Bartko, 1994). Three degrees of correlation were determined:

- Low correlation if ICC was  $< 0.4$
- Normal–good correlation if ICC was between 0.40 and 0.75
- Very good correlation if ICC was  $> 0.75$

Statistical significance was set at  $p < 0.05$ .

### 3. Results

The conventional preoperative treatment planning and the surgical interventions performed were carried out by the same surgeon, Dr. F. Hernández-Alfaro. A second surgeon, Dr. S. Aboul-Hosn, was responsible for converting the treatment planning into 3D images. This division of work ensured that data collection did not influence the results as different surgeons were responsible for the 3D planning and the surgical procedures performed.

Two features of the software program SimPlant® OMS 10.1 were tested:

#### (A) Correlation between surgical splints:

The level of concordance between conventional and CAD/CAM surgical splints was determined for each patient. Depending upon whether there was an error of  $< 1$  mm in one, two or three planes, the level of concordance was classified as 'low', 'moderate' or 'high' respectively. Table 3 shows the results of this comparative analysis. Analysis was carried out in all cases by the same surgeon, in the operating room. Levels of concordance classified as 'moderate' and 'high' were considered to be optimum results from the point of

view of the similarity between splints, since no difference was found in the final clinical result. Of the 16 patients included in the study, high concordance was found in 9 cases in which the splints manufactured using both methods gave almost identical results, coinciding in all three planes. In 6 cases, concordance was moderate. Similarity was found in two of the three planes, with differences of  $< 1$  mm. In only one case was the level of similarity low, with the surgical splints clearly differing when the preoperative planning was reproduced in surgery.

#### (B) Precision in the prediction of outcome:

Table 2 shows the Intraclass Correlation Coefficient in each of the measurements between the outcome predicted and the results obtained at 3 months after surgery. The results obtained were interpreted numerically, and classified as 'high', medium and 'low'. Using this classification, ten of the seventeen measurements studied showed a high degree of correlation. This was statistically significant ( $p < 0.05$ ) and shows a high degree of correlation between the predicted outcome and the final result in these ten measurements. In four of the measurements, the degree of correlation was medium, and in only three it was low. A high degree of correlation was found in the majority of the linear measurements and in some of the angular measurements of hard and soft tissue. Measurements in the occlusal plane, the mandibular plane or the maxillary plane did not show a high degree of correlation.

### 4. Discussion

Using 3D planning, a study was carried out of the accuracy of the software program SimPlant® Pro OMS 10.1 (Materialise®, Leuven, Belgium) in producing postoperative predictions and manufacturing surgical splints using CAD/CAM technology. This program not only assists in making diagnoses, as do other 3D-virtual imaging systems (Hing, 1989; Donatsky et al., 1992, 1997; Schlutes et al., 1998; D'Houthuille et al., 2005), but it also facilitates the manufacture of physical elements such as stereolithographic surgical splints. Surgical splints are vital in orthognathic surgery if predictable results are to be obtained. This is particularly so in bimaxillary surgery where complex movements are performed in the three planes (Ellis, 1999). A significant change has been brought about in the way in which surgical splints are manufactured since new technologies have been incorporated into the process. As a result model surgery is now being eliminated from clinical routine and its place is being taken by 3D-virtual simulations performed on computer screens. Surgery on plaster dental models, which is the method traditionally used, and not without its risks (Olszewski and Reychler, 2004), is a method that simulates the movement of the dental arches in surgery. However, only the patients' teeth are represented in three dimensions in these models. None of the facial skeleton on which the surgeon works intraoperatively, modifying and mobilising it, is represented. Three-dimensional planning enables the craniofacial skeleton to be viewed at all times when planning treatment and mobilising osteotomized bone structures. Using the software option 'prediction of outcome', changes brought about in soft tissue can be visualised. Data is thus made available which cannot be provided by model surgery in articulators or 2D analysis. Being able to predict postoperative results is the great advantage of a 3D treatment planning system considering the large number of patients undergoing this type of surgery for aesthetic reasons (Kiyak et al., 1988). When using conventional methods there is an intrinsic difficulty in importing 2D cephalometric data to model surgery. The movements of rotation and translation are controlled not well enough during model surgery in the articulator. There is an intrinsic risk of error at this stage of the study. In articulators, no anatomic

**Table 3**  
Level of concordances results.

Cases	Level of concordance between the conventional surgical splints and the CAD/CAM surgical splints
1	High
2	Medium
3	Low
4	High
5	High
6	High
7	High
8	Medium
9	High
10	High
11	Medium
12	Medium
13	High
14	High
15	Medium
16	Medium

references such as the facial or chin midline are available as they are in 3D images.

It is important to mention three points at which conventional model surgery can lead to error (Olszewski and Reychler, 2004):

- when transferring the models to the articulator: as a result of the characteristics of the articulator; patients' anatomy at the level of the external auditory canal and or the nasal dorsum; or patients' cooperation when cast of the facial arch is being made.
- when drawing the vertical and horizontal lines of reference in the models: this line is drawn by hand using 2-dimensional instruments (ruler and calliper) on plaster casts that do not represent patients' bone structure or the osteotomy lines that will be used in surgery.
- when repositioning the models, when transferring and rotating: these complex movements in three planes of the space must be exactly reproduced in surgery. The problem is the only 3D structures, that are available are the models of the dental arches and no reproduction of the facial skeleton is provided, so any interferences between bone structures will not be reproduced in the simulation in the articulator.

In our opinion, simulations performed using articulators may also lead to error at the centre of rotation of the mandibular condyle which is the same for all patients when working with a semi-adjustable articulator. This is not the case in reality. Working with 3D representations of the anatomic structures of each patient can provide a more precise vision of how the condyle will rotate when the mandible is mobilised. An advantage of the new system is that the condyle–fossa relationship in centric relation remains stable throughout the planning process.

When using 3D planning, all the necessary information is provided in images which can be manipulated on a PC, whilst conventional planning makes it necessary to obtain data from different studies (radiographs, models and articulators, face bow, etc.) and to interpret the data before being able to develop a treatment plan. In our study, 3D models of the patients were obtained for our treatment planning, not for the purposes of surgery but to obtain more precise details of their dental structures. This step may well be eliminated in future if the new technologies enable more precise images of patients' teeth to be obtained either as a result of advances in CBCT itself, the development of intraoral scanners, or optical laser scanners. Working in 3D enables surgeons to get nearer to the reality with which they have to work in the operating room. The mobilisation of osteotomized bone structures is complex since it combines rotation and translation in three planes.

Patients with severe asymmetry can be treated using this new technology (Hernández-Alfaro et al., 2006). In just one simulation the maxillomandibular complex can be aligned in the correct position and the skeletal asymmetry then corrected. It enables asymmetry of the maxillomandibular complex to be compared with the rest of the facial skeleton in a frontal view so that the anatomical region causing the facial asymmetry can be seen easily (Gateno et al., 2007). The diagnosis can be shared with the patient using a 3D image that can be easily understood.

Another of the advantages of the software program studied is that it can be used by a technician following the instructions of the surgeon. Data can be sent quickly and easily to any part of the world using the Internet, thereby making the most of the advantages afforded by telemedicine. Using this methodology, physical elements used for treatment planning can be eliminated from clinical practice. Treatment plans can be stored online and the space normally taken up by materials used in conventional planning, saved.

We studied the accuracy of the Cad/Cam technology in creating surgical splints that would transfer our surgical planning to the

operating room. There is a significant difference between the manufacturing of the splints with Cad/Cam technology and conventional methodology, and we compared surgical splints manufactured using both techniques in the operating room to objectively evaluate the differences numerically. The high degree of similarity found between both types of surgical splints leads us to conclude the Cad/Cam method is a valid and reliable technique for designing surgical splints that will accurately reproduce our 3D computerised planning in the operating room.

This change of technique results in the production of surgical splints created from the improvement in quality and quantity of the diagnostic data thanks to the incorporation of all the information of the patient in one single 3D image and the elimination of the need for several different sources of information (face bow, model surgery, photographs, multiple radiographs).

Considering the post-surgical prediction results, we would describe them as encouraging but not sufficiently accurate. As shown in the Table 2 the linear measurements on bone structures gave more accurate results than the angular measurements or those where the teeth and/or soft tissues were studied. Because of this we feel that the software studied still does not allow an absolutely accurate prediction of results, especially with the soft tissues. We associate this lack of accuracy to two factors:

- 1 difficulty in gathering some of the dental structures with good accuracy
- 2 great variability of the behaviour of the soft tissues due to factors such as swelling, the surgical approach, and the patient's muscle tone.

The systems presented by other authors (Xia et al., 2001; Gateno et al., 2003; Swennen et al., 2007, 2008, 2009a,b,c; Metzger et al., 2008; Schendel and Jacobson, 2009) differ from the system we propose in two aspects:

- The way in which the data is obtained
- The type of software used.

This makes it difficult to compare the different 3D planning software programs. A major drawback in this technique of treatment planning is that the images of the patients' dental structures obtained using CBCT or CT-scans are not accurate enough. Different techniques are described (Xia et al., 2007; Swennen et al., 2009a,b,c; Schendel and Jacobson, 2009) to those described in this study, although all of them require a mixture of images of teeth and hard and soft tissue, thus complicating the process of acquiring 3D images.

## 5. Conclusions

Our experience in this study has led us to the following conclusions:

- using 3D imaging, it is possible to manufacture CAD/CAM surgical splints that can precisely reproduce our treatment planning in the operating room
- postoperative predictions are reliable in some areas and further study is required to confirm the results obtained in this study. Further progress is required in the development of the 3D imaging of soft tissue by introducing mathematical algorithms that precisely represent the postoperative changes that occur in facial soft tissue
- 3D imaging facilitates the surgeon's evaluation of malformations involving asymmetry of hard and soft tissue and phenomena such as canting

- 3D treatment planning facilitates data management as all information is stored in computer files which can be easily managed online
- 3D planning facilitates the reproducibility of treatment planning
- the need to construct dental models may be eliminated when further progress is made in the acquisition of 3D images of dental structures. This may come with the introduction of intraoral scanners into clinical practice.

Three-dimensional planning is currently a working technique that is being incorporated into clinical practice. CAD/CAM technology used to manufacture surgical splints for use in orthognathic surgery is the next stage in the evolution of computerised 3D treatment planning since it enables 3D physical structures to be obtained from 3D images. As a result of our experience in this study, and the results obtained by other research groups (Gateno et al., 2003; Hernández-Alfaro et al., 2006; Gateno et al., 2007; Xia et al., 2007; Metzger et al., 2008; Swennen et al., 2009a,b,c) this method of planning and manufacture of surgical splint is now practical.

Being able to use a 3D-virtual environment for planning and simulating surgery – Computer Aided Surgical Simulation (CASS) – provides surgeons with the best possible scenario for preoperative treatment planning.

## References

- Bartko JJ: Measures of agreement: a single procedure. *Stat Med* 13(5–7): 737–745, 1994
- D'Hauthuille C, Taha F, Devauchelle B, Testelin S: Comparison of two computer-assisted surgery techniques to guide a mandibular distraction osteogenesis procedure. Technical note. *Int J Oral Maxillofac Surg* 34: 197–201, 2005
- Donatsky O, Hillerup S, Bjorn-Jorgensen J, Jacobsen PU: Computerized cephalometric orthognathic surgical simulation prediction and postoperative evaluation of precision. *Int J Oral Maxillofac Surg* 21: 199–203, 1992
- Donatsky O, Born-Jorgensen J, Holmqvist-Larsen M, Hillerup S: Computerized cephalometric evaluation of orthognathic surgical precision and stability in relation to maxillary superior repositioning combined with mandibular advancement or setback. *J Oral Maxillofac Surg* 55(10): 1071–1079, 1997
- Eckhardt CE, Cunningham SJ: How predictable is orthognathic surgery? *Eur J Orthod* 26: 303–309, 2004
- Ellis III E: Bimaxillary surgery using an intermediate splint to position the maxilla. *J Oral Maxillofac Surg* 57: 53–56, 1999
- Gateno J, Xia JJ, Teichgraeber JF, Christensen AM, Lemoine JJ, Liebschner MA, et al: Clinical feasibility of computer-aided surgical simulation (CASS) in the treatment of complex craniomaxillofacial deformities. *J Oral Maxillofac Surg* 65: 728–734, 2007
- Gateno J, Xia J, Teichgraeber JF, Rosen A, Hultgren B, Vadnais T: The precision of computer-generated surgical splints. *J Oral Maxillofac Surg* 61(7): 814–817, 2003
- Hernández-Alfaro F, Mair D, Martí C, Biosca MJ: Planificación virtual y diseño de férulas CAD/CAM en cirugía Ortognática: ¿una nueva era? *Rev Esp Ortod* 36: 363–370, 2006
- Hing NH: The accuracy of computer generated prediction tracings. *J Oral Maxillofac Surg* 18: 148, 1989
- Juergens P, Schwenger-Zimmerer K, Zeilhofer HF: Comparison of 3D-visualization, planning and navigation tools in orthognathic surgery. *J Craniomaxillofac Surg* 34(1): 13, 2006
- Kiyak HA, Vitaliano PP, Crinean J: Patients expectations as predictors of orthognathic surgery outcomes. *Health Psychol* 7: 251–268, 1988
- Marchetti C, Bassani L, Mazzoni S, Ozeri E: The Simplant CMF software: a new way of planning in orthognathic surgery. *J Craniomaxillofac Surg* 34(1): 32, 2006
- Marchetti C, Bianchi A, Bassi M, Gori R, Lamberti C, Sarti A: Mathematical modelling and numerical simulation in maxillo-facial virtual surgery (VISU). *J Craniofac Surg* 18(4): 826–832, 2007
- Metzger MC, Hohlweg-Majert B, Schwarz U, Teschner M, Hammer B, Schmelzeisen R: Manufacturing splints for orthognathic surgery using three-dimensional printer. *Oral Surg Oral Med Oral Pathol Oral Radiol Endod* 105: e1–e7, 2008
- Olszewski R, Reyehler H: Les limites de la chirurgie des modèles en chirurgie orthognathique: implications théoriques et pratiques. *Rev Stomatol Chir Maxillofac* 105(3): 165–169, 2004
- Olszewski R, Tanesy O, Cosnard G, Zech F, Reyehler H: Reproducibility of osseous landmarks used for computer tomography based three-dimensional cephalometric analyses. *J Craniomaxillofac Surg* 38(3): 214–221, 2010
- Schendel SA, Jacobson R: Three-dimensional imaging and computer simulation for office-based surgery. *J Oral Maxillofac Surg* 67(10): 2107–2114, 2009
- Schlutes G, Gaggl A, Karcher H: Accuracy of cephalometric and video imaging program Dentofacial Planner Plus in orthognathic surgical planning. *Comput Aided Surg* 3: 108–114, 1998
- Swennen GR, Mommaerts MY, Abeloos J, De Clercq C, Lamoral P, Neyt N, et al: The use of a wax bite wafer and a double computed tomography scan procedure to obtain a three-dimensional augmented virtual skull model. *J Craniofac Surg* 18(3): 533–539, 2007
- Swennen GR, VanHove J, De Clercq C, Abeloos J, Lamoral P, Lippens F, et al: 3D planning of orthognathic surgery – a prospective study. *J Craniomaxillofac Surg* 36(1): S90, 2008
- Swennen GR, Mommaerts MY, Abeloos J, De Clercq C, Lamoral P, Neyt N, et al: A cone-beam CT based technique to augment the 3D virtual skull model with a detailed dental surface. *Int J Oral Maxillofac Surg* 38(1): 48–57, 2009a
- Swennen GR, Mollemans W, Schutyser F: Three-dimensional treatment planning of orthognathic surgery in the era of virtual imaging. *J Oral Maxillofac Surg* 67(10): 2080–2092, 2009b
- Swennen GR, Mollemans W, De Clercq C, Abeloos J, Lamoral P, Lippens F, et al: A cone-beam computed tomography triple scan procedure to obtain a three-dimensional augmented virtual skull model appropriate for orthognathic surgery planning. *J Craniofac Surg* 20(2): 297–307, 2009c
- Xia J, Ip HH, Samman N, Wang D, Kot CS, Yeung RW, et al: Computer-assisted three-dimensional surgical planning and simulation: 3D virtual osteotomy. *Int J Oral Maxillofac Surg* 29: 11–17, 2000
- Xia J, Ip HH, Samman N, Wong HT, Gateno J, Wang D, et al: Three-dimensional virtual-reality surgical planning and soft-tissue prediction for orthognathic surgery. *IEEE Trans Inf Technol Biomed* 5(2): 97–107, 2001
- Xia JJ, Gateno J, Teichgraeber JF, Christensen AM, Lasky RE, Lemoine JJ, et al: Accuracy of the computer-aided surgical simulation (CASS) system in the treatment of patients with complex craniomaxillofacial deformity: a pilot study. *J Oral Maxillofac Surg* 65(2): 248–254, 2007